

See discussions, stats, and author profiles for this publication at: <https://www.researchgate.net/publication/332131136>

# All-On-Four Treatment Concept in Dental Implants: A Review Articles

Article · March 2019

DOI: 10.32474/SCSOAJ.2019.02.000142

CITATIONS

11

READS

4,085

6 authors, including:



**Shakhawan M. Ali**

University of Sulaimani

24 PUBLICATIONS 188 CITATIONS

[SEE PROFILE](#)



**Zanyar Amin**

Teaching hospital/ Sulaimani

10 PUBLICATIONS 23 CITATIONS

[SEE PROFILE](#)



**Payman Kh. Mahmud**

Kurdistan Board for Medical Specialties

13 PUBLICATIONS 36 CITATIONS

[SEE PROFILE](#)

# All-On-Four Treatment Concept in Dental Implants: A Review Articles

Shakhawan M. Ali<sup>1\*</sup>, Zanyar M. Amin<sup>2</sup>, Rebwar A Hama<sup>3</sup>, Hawbash O Muhamed<sup>3</sup>, Rozhyna P Kamal<sup>4</sup> and Payman Kh Mahmud<sup>5</sup>

<sup>1</sup>Lecturer at Department of Oral and Maxillofacial Surgery, Shar Surgical Emergency Hospital, Sulaimany, Kurdistan region, Iraq

<sup>2</sup>Lecturer at Department of Oral and Maxillofacial Surgery, School of Medicine, Faculty of Dentistry, University of Sulaimani, Kurdistan Region, Iraq

<sup>3</sup>KBMS trainee, Maxillofacial Department, Sulaimany teaching hospital, Sulaimany, Kurdistan region, Iraq

<sup>4</sup>KBMS trainee, Restorative Department, Shorsh dental teaching center, Sulaimany, Kurdistan region, Iraq

<sup>5</sup>Lecturer at Department of Oral and Maxillofacial medicine, Shar teaching hospital, Kurdistan Region, Iraq

\*Corresponding author: Shakhawan M. Ali, Board certified Oral and Maxillofacial Surgery, Shar teaching hospital, Sulaimany, Kurdistan region, Iraq

Received:  March 03, 2019

Published:  March 21, 2019

## Abstract

Edentulism has been demonstrated to have negative social and psychological effects on individuals that include adverse impacts on facial and oral esthetics, masticatory function and speech abilities, that when combined, are translated into significant reductions in patients' quality of lives. It is well-known that immediate placement of implants is a challenging surgical procedure that requires proper treatment planning and surgical techniques. There are several prosthetic options to rehabilitate severely atrophic maxillae and mandibles have been developed such as conventional complete dentures, implant supported removable and implant supported fixed prosthesis. Implant supported prosthesis may not be feasible in many conditions because of the vicinity of vital anatomical structures, poor bone quality and quantity.

The implant technology developed as the all-on-four concept is offered as an alternative to conventional implant applications. In the all-on-four technique, 4 implants are placed in the inter foraminal region in the mandible and in the pre-maxillary region in total edentulism cases. An exception is the all-on- Four concept, which uses only 4 implants to support an acrylic, screw-retained provisional prosthesis delivered on the day of implant placement, followed by a definitive prosthesis approximately 4 months later. The patient can also be benefited with the immediate rehabilitation of edentulous arches which helps maintaining self-confidence and quality of life.

**Keywords:** All on four concept; Dental implant; Tilted implant; Severe atrophy

**Abbreviation:** CT: Computerized Tomography; Ncm: Newton centimeter ; mm: Millimeter

## Introduction

One of the greatest challenges in implant dentistry is the treatment of patients with severely atrophic jaws. Such atrophy can be horizontal or vertical or both; even if sufficient vertical bone is present, lack of ridge width can still preclude treatment with implants that are 4 mm in diameter or wider. Over the years, many techniques, procedures, and materials have been introduced to solve the complex problems associated with treatment of atrophic jaws. One early approach in the posterior maxilla was to augment the sinus in conjunction with the simultaneous placement of

implants [1-3]. In cases where the mandibular bone height is less than 12.0 mm, tissue augmenting techniques including bone ridge expansion and bone grafts are typically made necessary to allow the placement of traditional dental implants. Despite their widespread use, these techniques are clinically very challenging and display higher levels of tissue and implant morbidity.

Modern oral rehabilitation strategies based on the utilization of dental implants and immediate loading techniques, have been demonstrated to allow for the rapid and efficient restoration of

patients with superior esthetic and masticatory properties, while reducing the morbidity and damage to both soft and hard tissues. In some cases of the completely edentulous patients, implant supported prosthesis treatment is almost impossible without complex techniques such as nerve transposition and grafting in the posterior maxilla and mandible. A solution for such situations is the All-on-4 concept [4]. Implant supported prosthesis may not be feasible in many conditions because of the vicinity of vital anatomical structures like mandibular canal or maxillary sinus. Over the years, many techniques, procedures, and materials have been introduced to solve the complex problems associated with treatment of atrophic jaws and avoid the vicinity of vital anatomical structures such as the use of short implants, alveolar distraction osteogenesis, guided bone generation, use of intraoral and extraoral autogenous bone grafts, nerve repositioning etc. The high cost, time and morbidity associated with such approaches have limited their application.

At the beginning of the millennium, distally tilted implants were proposed, enabling the use of denser bone located in the anterior mandible for improving bone anchorage, and replacement of posterior teeth without extended cantilevers and avoiding bone grafting procedure [5]. The "all-on-four" treatment concept was

developed to maximize the use of available remnant bone in atrophic jaws, allowing immediate function and avoiding regenerative procedures that increase the treatment costs and patient morbidity, as well as the complications inherent to these procedures [6].

### History of the All-on-4® concept

One of the early designs of the All-on-4 style concept can be traced back to Mattson and colleagues, in 1999 whereby they treated, patients with severely resorbed edentulous maxilla by inserting 4 to 6 implants in the premaxilla to avoid sinus augmentation and successfully restored them with fixed prosthesis with 12 teeth supported by superstructure [7]. In 2000, Krekmanov and colleagues were also able to demonstrate posterior tilted implant-supported prosthesis was possible. The All-on-4 immediate loading concept was developed, institutionalized and systematically analyzed in the 2003 by a dentist Paulo Malo and colleagues [8]. This concept uses 2 vertical anterior implants in conjunction with 2 distally tilted inclined implants with their apices positioned anterior to the sinus wall or mental foramen (Figure 1). It involves the use of straight and angled multiunit abutments, which support a provisional, fixed, and immediately loaded, full arch prosthesis. It has been developed to maximize the use of available bone and allows immediate function [9] (Figure 2).

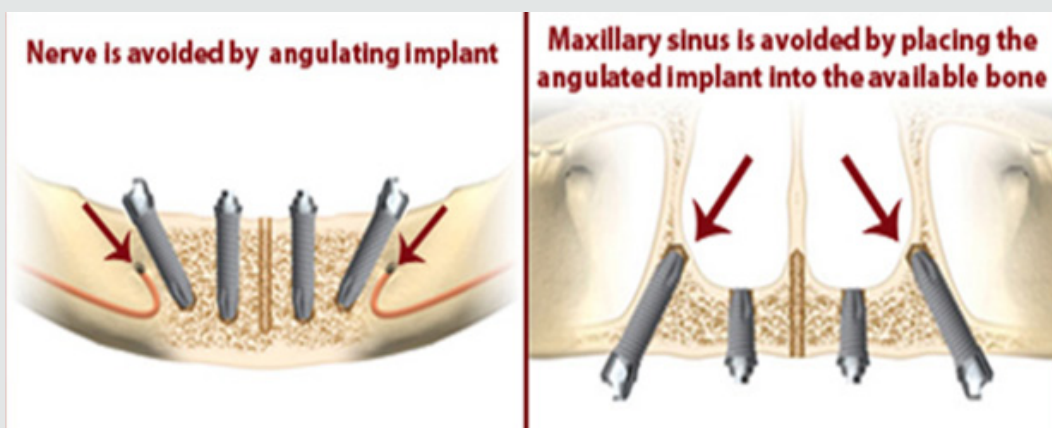


Figure 1: Show how vital structure avoided in All on 4 Concept.

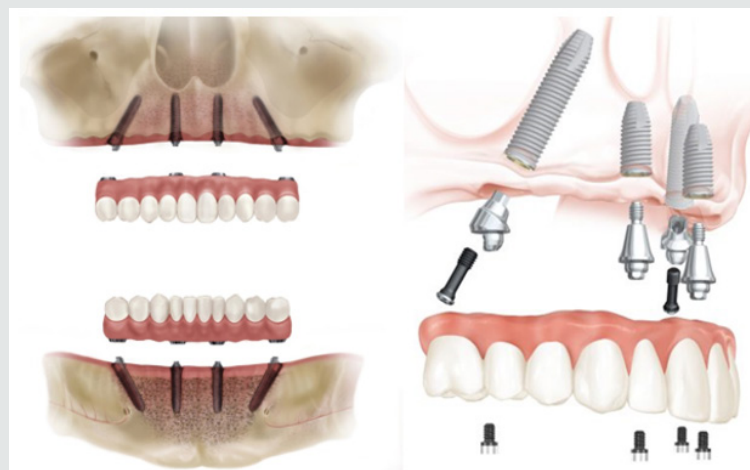


Figure 2: Show All on 4 concept design and multi-unit abutment.

In this technique, four implants are placed in the anterior region of the jaw between the two mental foramina in the mandible and between the mesial walls of the maxillary sinus in the maxilla. The two anterior implants follow the jaw anatomy and the two distal implants are tilted at 45° angulation (Figure 1). Many long-term studies and published data on the All-on-4 concept reported cumulative survival rates between 92.2% and 100% [10].

### Treatment Planning

The All-on-4 clinical solution has been developed to

- a. Maximize the use of available bone
- b. To allow for Immediate Function.

### General Considerations

- a. Ability to achieve primary implant stability (35 – 45 Ncm)
- b. No severe parafunctions
- c. To diminish the cantilever, tilt the posterior implants.
- d. Does not require a wider opening of the mouth
- e. It is advisable to place implants between extraction sockets.
- f. Indicated with a minimum bone width of 5mm and minimum bone height of 10mm from canine to canine in maxilla and 8mm in mandible.
- g. If angulation is 30° or more, the tilted implants can be splinted. For tilted posterior implants, the distal screw access holes should be located at the occlusal face of the first molar, the second premolar, or the first premolar.

### Advantages of the All-on-4 Concept

- I. Avoids complex surgery,
- II. Less invasive procedure for the pt.
- III. Graft less procedure.
- IV. Implants well-spaced, good biomechanics, easier to clean, immediate function and aesthetics
- V. Simplified surgical & prosthetic procedure.
- VI. Reduced cost due to less number of implants.
- VII. High success rates.
- VIII. Angled posterior implants:-
  - a. Avoid anatomical structures
  - b. Allow longer implants anchored in better quality bone
  - c. Reduces posterior cantilever

### Disadvantages

- a. Length of cantilever in the prosthesis cannot be extended beyond the limit.

b. Free hand arbitrary surgical placement of implant is not always possible as implant placement is completely prosthetically driven.

c. It is very technique sensitive and requires elaborate pre-surgical preparation such as CAD/CAM, surgical splint [11].

## Treatment Protocol Consists of Two Phases: Surgical and Prosthetic

### I. surgical protocol

- I. Step 1:** Selection of case satisfying the inclusion criteria
- II. Step 2:** Planning implant placement using All-On-4 Guide (Preferred)
- III. Step 3:** Location of Maxillary Antrum and Mental Foramen with All-On-4 Guide
- IV. Step 4:** Implant placement done following the protocols

The surgical guide is placed into a 2 mm osteotomy that is made in the midline position of the maxilla or mandible and the titanium band is contoured to follow the arc of the opposing arch. The mandibular guide also assists in retracting the tongue. The vertical lines on the guide are used as a reference for drilling at the correct angulation, which should not be greater than 45°. Angulated pins and denture can also be used as templates. The two most anterior implants follow jaw anatomy in direction (lingual tilting in cases of severe mandibular resorption). The two posterior implants are inserted just anterior to the foramina or maxillary sinus and tilted distally approximately 30°– 45° relative to the occlusal plane. Implant torque is set to greater than 35 Ncm. If the torque values for three or more implants are below 35 Ncm, a 2-stage technique is preferred [9].

### II. prosthetic phase

17° multiunit abutments and 30° angulated, Straight Abutments with different collar heights are placed onto the implants. These are used to achieve the correct access allowing relative parallelism and so that the rigid prosthesis can be seated passively [12]. For provisional prosthesis fabrication on the day of surgery (2–3 hours after surgery), the impression copings are placed onto the multiunit abutments which are then splinted with autopolymerising resin and wire bars. It ensures an accurate transfer without accidental displacement of the impression copings and impression is made. Protective healing caps are placed on the abutments while provisional is being made. Acrylic provisional screw retained prosthesis is torqued to 15 Ncm. Only soft diet is recommended. For final prosthesis (4–6 months after initial implant placement), if the implants are judged stable, provisional restoration is removed and bite is registered. Multiunit laboratory analogs are attached to the provisional and then it is mounted on an articulator against a counter model. The prosthesis is indexed with putty. Resin pattern is fabricated in sections and the sections are joined in the patient's

mouth. This resin pattern gets scanned and framework is made by CAD/CAM technology. After try-in of the framework, final prosthesis is fabricated and delivered. Final prosthesis can be a metal-acrylic resin with a titanium framework and acrylic resin prosthetic teeth, or a metal ceramic prosthesis with titanium framework and all ceramic zirconia crowns [12].

## Discussion

A recent shift in practice paradigm has been to minimize treatment costs and patient morbidity while providing the most satisfying patient-centered treatment outcomes according to the state of the art of dental practice. The "All on-Four" treatment concept is an attempt to reach these objectives by providing relatively straight forward, predictable treatment option to rehabilitate edentulous patients with a high outcome of Quality of life [13]. Babbush et al. described a protocol of combining the 3.5-mm-diameter Nobel Active implants with the All-on-4 concept and reported on the results of 227 implants after 1 to 3 years of Follow-up. The cumulative survival rate was 98.7% at the end of 3 years, with a 100% prosthetic survival rate [14]. Paul Malo did retrospective clinical studies and found that long-term outcomes ( up to 10 years ) of 245 patients with completely edentulous mandibles rehabilitated with the All-on-4 treatment concept and reported cumulative implant survival rates of 93.8% and 94.8% using the patient and implant as units of analysis, respectively [15] Lopes et al. did a prospective study to evaluate the medium- and long-term outcomes of the rehabilitation of completely edentulous jaws in immediate function with the All-on-4 treatment concept using a computer-guided surgical protocol and reported an overall 96.6% cumulative survival rate after 5 years of follow-up [16]. Published studies on the All on-Four concept have shown cumulative survival rates to range between 92.2% and 100% [10]. clinical research over the past decade has shown that more than 4 dental implants to support a full, fixed (non-removable) bridge is typically not necessary, and that placing more than 4 implants does not increase success rates[17]. Owing to the freedom of tilting, the implants can be anchored in dense bone structures (anterior bone with higher density) and well spread anteriorly-posteriorly giving an effective prosthetic base. By reducing the number of implants to four, each implant can be placed without coming into conflict with adjacent implants. This treatment approach, using tilting and few implants rather than inserting several implants competing for space, has demonstrated good results.

## Conclusion

The "All-on-4" treatment concept seems to be an alternative option for rehabilitating edentulous jaws compared with advanced surgical approaches without using removable prostheses. It is a cost-effective procedure, decreasing the treatment times, the morbidity and allowing a higher patient quality of life. Placement of dental implants previously in attempts to treat the severely

resorbed maxilla and mandible has had only limited success. But the rehabilitation of completely edentulous, atrophied maxilla and mandible by the placement of implants using the All-on-Four protocol gives new hope for a perceivable success, while becoming a promising treatment method of choice and standard in the care for severely compromised patients.

## References

1. Boyne PJ, James RA, (1980) Grafting of the maxillary sinus floor with autogenous marrow and bone. *J Oral Surg* 38(8): 613-616.
2. Tatum H, (1986) Maxillary and sinus implant reconstruction. *Dent Clin North Am* 30(2): 207-229.
3. Neamat AH, Ali SM, Boskani SW, Kh Mahmud P (2017) An indirect sinus floor elevation by using piezoelectric surgery with platelet-rich fibrin for sinus augmentation: A short surgical practice. *Int J Case Rep Images* 8(6): 380-384.
4. Rosa, (2018) All-on-four Protocol in an Atrophic Mandible. *The Open Dentistry Journal* 12: 1004-1010.
5. Thumati P, Reddy M, Mahantshetty M, Manwani R (2015) "All-On-4/DIEM 2" A concept to rehabilitate completely resorbed edentulous arches. *J Dent Implant* 5(1): 76-81.
6. Malo P, Rangert B, Dvarsater L (2000) Immediate function of Branemark implants in the esthetic zone: a retrospective clinical study with 6 months to 4 years of follow-up. *Clin Implant Dent Relat Res* 2(3): 138-146.
7. Chan MH, Holmes C, (2015) Contemporary "All-on-4" concept. *Dent Clin North Am* 59(2): 421-470.
8. Krekmanov L, Kahn M, Rangert B, Lindström H, (2000) Tilting of posterior mandibular and maxillary implants for improved prosthesis support. *Int J Oral Maxillofac Implants* 15(3): 405- 414.
9. Sharma S, Luthra R, Makkar M, Singh P, Pathania P, (2017) All-on-4 treatment concept - a review. *J Pharm Biomed Sci* 7 (3): 53-56.
10. Thumati P, Reddy M, Mahantshetty M, Manwani R, (2015) "All-On-4/DIEM 2" A concept to rehabilitate completely resorbed edentulous arches. *J Dent Implant* 5(1): 76-81.
11. Anandh B, Lokesh B, Ebenezer V, Jimson S, Parthiban JJ, (2015) All on Four - The Basics. *Biomed Pharmacol J* 8.
12. Taruna M, Chittaranjan B, Sudheer N, Tella S, Abusaad M, (2014) Prosthodontic perspective to All-On-4® concept for dental implants. *J Clin Diagnos Res* 8(10): ZE16-ZE19.
13. Rangert B, Jemt T, Jörneus L, (1989) Forces and moments on Brånemark implants. *Int J Oral Maxillofac Implants* 4(3): 241-247.
14. Babbush CA, Kanawati A, Brokloff J (2013) A new approach to the all-on-four treatment concept using narrow platform nobel active implants. *J Oral Implantol* 39(3): 314-325.
15. Maló P, Araújo Nobre M, Lopes A, Ferro A, et al. (2015) All-on-4® treatment concept for the rehabilitation of the completely edentulous mandible: a 7-year clinical and 5-year radiographic retrospective case series with risk assessment for implant failure and marginal bone level. *Clin Implant Dent Relat Res* 17 Suppl 2 :e531-e541.
16. Lopes A, Maló P, de Araújo Nobre M, Sanchez-Fernández E, (2015) The Nobel Guide® All-on-4 treatment concept for rehabilitation of edentulous jaws: a prospective report on medium- and longterm outcomes. *Clini Implant Dent Relat Res* 17 Suppl 2: e406-e416.
17. Brånemark PI, Svensson B, van Steenberghe D, (1995) Ten-year survival rates of fixed prostheses on four or six implants ad modum Brånemark in full edentulism. *Clin Oral Implants Res* 6(4): 227-231.



This work is licensed under Creative Commons Attribution 4.0 License

To Submit Your Article Click Here: [Submit Article](#)

DOI: [10.32474/SCSOAJ.2019.02.000142](https://doi.org/10.32474/SCSOAJ.2019.02.000142)



### Surgery & Case Studies: Open Access Journal

#### Assets of Publishing with us

- Global archiving of articles
- Immediate, unrestricted online access
- Rigorous Peer Review Process
- Authors Retain Copyrights
- Unique DOI for all articles